

## Effect of fluoroscopy in central vein catheterization in children

Use of fluoroscopy in central vein catheterization in children

Nevin Aydın<sup>1</sup>, Osman Esen<sup>2</sup>, Gülseren Yılmaz<sup>1</sup>

<sup>1</sup>Department of Anesthesiology and Reanimation, University of Health Sciences, Kanuni Sultan Süleyman Training and Research Hospital

<sup>2</sup>Department of Anesthesiology and Reanimation, Vocational School Of Health, Istinye University, Istanbul, Turkey

### Abstract

**Aim:** In this study, we aimed to evaluate the effect of fluoroscopy on the prevention of malposition during placement of central venous catheters (CVC) in children, complications that occur during the procedure and follow-up and associated risk factors.

**Material and Methods:** A total of 87 central venous catheter placement procedures performed in 59 pediatric patients under fluoroscopy between 2014 and 2016 were included in the study. Demographic data, catheter insertion site, indication, number of attempts, catheter diameter, insertion time, complications during insertion and follow-up were recorded.

**Results:** The mean age of the cases was 5 months (1-28 months), and the mean body weight was 4.64 kg (1-14). Catheter insertions were mostly performed through the jugular vein. The femoral location was used in emergency situations in 12 patients (13.7%); 36.8% of catheter placements were used to provide peripheral vascular access, 59.8% were used for parenteral nutrition, intravenous fluid and inotropic support, and 3.4% for chemotherapy.

Complications occurred during catheter placement in 29 of the patients. The most common intervention complication was arterial puncture. Complications in the right jugular and subclavian regions were more common than in other regions ( $p=0.015$ ). Malposition or kinking of the catheter was not observed during the placement. Arterial puncture and pneumothorax/hemothorax were encountered more frequently as the number of attempts increased ( $p=0.001$ ). Catheter-related bloodstream infection was the most common complication and was observed in 11 (12.6%) catheters.

**Discussion:** Various complications may be encountered during placement and monitoring in CVC applications in pediatric patients. Using fluoroscopy during placement reduces complications such as malposition and arrhythmia.

### Keywords

Child, Catheterization, Fluoroscopy

DOI: 10.4328/ACAM.20944 Received: 2021-11-10 Accepted: 2021-12-14 Published Online: 2021-12-19 Printed: 2022-03-15 Ann Clin Anal Med 2022;13(Suppl 1): S1-5

Corresponding Author: Osman Esen, Zümrütevler Mahallesi, Handegül Sokak, No:98/16, Maltepe, İstanbul, Turkey.

E-mail: drosmansen@gmail.com P: +90 505 677 13 85 F: +90 216 457 38 00

Corresponding Author ORCID ID: <https://orcid.org/0000-0001-6280-5064>

## Introduction

Central venous catheter application has been playing an important role in monitorization and treatment of the patients in critical condition. CVC is a method used for interventional operations such as hemodynamic monitoring, liquid and medicinal applications in situations necessitating long-term follow-up and wide vascular access like chemotherapy, infusion of blood and blood components, parenteral nutrition, hemodialysis and plasmapheresis [1-3]. Subsequent to successful applications on adults, because of additional advantages CVC has brought to pediatric patients, its scope of utilization and application has been broadened. Whereas the complications may lessen when applied by experienced personnel, life-threatening complications may be encountered. Catheter placement intervention (operation) should be conducted by experienced staff in a sterile environment; complications, which may emerge during the operation and monitorization must be taken into consideration, and the catheter must be maintained carefully. In this study, it was aimed to evaluate emerging complications during the placement of central venous catheters guided by fluoroscopy, and during their monitoring in pediatric patients; and also assessment of related risk factors and effects of utilizing fluoroscopy on preventing malposition in CVC applications.

## Material and Methods

Following the ethics committee approval, 87 central venous catheter insertion incidences and 59 pediatric patients subject to these applications between 2014-2016 in Kanuni Sultan Süleyman Training and research hospital anesthesiology and reanimation clinic, were evaluated retrospectively. For all the patients catheterized, age, weight, location of the insertion, number of insertions, the diameter of the catheter, the clinic where patient of concern is monitored, indications of insertion and removal of catheter, period of catheterization, complications during the insertion and catheterization process have been recorded.

Catheter complications were divided into two groups: Complications that emerged during insertion, and complications emerged during monitorization. Complications that emerged during insertion were assessed according to subtopics as arterial puncture, pneumothorax/hemothorax, malposition, and other complications (arrhythmia etc.); whereas complications that emerged during monitorization were evaluated for such subtopics as infection, thrombosis, catheter dysfunction, and other complications (hydrothorax etc.).

Subclavian vein, internal jugular vein and femoral vein were preferred for catheterization. All the catheters were applied in the operation room by two experienced anesthesiology and reanimation specialists through fluoroscopic guidance. All patients were sedated and anesthetized prior to the insertion, and all were intubated during the operation. For skin antisepsis, the location of insertion was wiped with 70% alcohol and sterilized with 10% povidone-iodine. The area of intervention was covered with a sterilized cloth. Personnel conducting the operation used mask, bonnet, and sterilized gown.

During the intervention, in addition to the physician realizing the operation, the patients were monitored by another

anesthesiology and reanimation specialist with respect to hemodynamics and oxygenation. All the catheters were inserted under fluoroscopic guidance with landmark technique and seldinger method. According to the body weight of the subjects 4F, 5F, and 5.5F double-lumen temporary central venous catheters were used. After catheter location was immobilised by suture, it was covered with a transparent poliurethane cloth free of chlorhexidine, and the location was treated with medical dressing daily. After failing interventions, catheter insertion has been applied from a different location. Incidents where none of the locations could be catheterized were evaluated as unsuccessful. None of the patients were applied cut-down.

For catheter intervention, thrombocyte and normal prothrombin over 50.000/mm<sup>3</sup>, partial thromboplastin time, and INR were considered as prerequisites. In patients who can not meet the conditions, but have been in need for urgent catheterization, the femoral region was the primary location of choice. For subclavian and jugular catheters, the area between the superior vena cava and right atrium, whereas for femoral catheters, inferior vena cava had been acknowledged as the appropriate locations for placement. Once the location has been confirmed and has been tested for complications, catheter was stabilized. For patients catheterized more than two days, the growth of pathogens in one or more blood cultures obtained from the third day of insertion to one day after the catheter extraction, without any relation to other infection sources, provided that one of the symptoms of fever (>38 C), trembling or hypotension is present in the patients of any age, whereas one of the symptoms of fever (>38 C), hypothermia (<36 C), apnoea or bradycardia is present in the patients with ages less than one year and that the positive lab results are related to no other infection source; has been considered as "blood stream infection related to catheterization". Since the study has been retrospective, catheter entry infection and tunnel infection could not be assessed.

## Statistical Analysis

The SPSS statistics program (IBM SPSS Statistics for Windows Version 16.0, SPSS Inc., and Chicago, IL, USA) was utilized. In evaluation, parametric numerical data were presented as mean  $\pm$  standard deviation, whereas non-parametric numerical data were given as median (minimum-maximum). Categorical data were given as (%). The Chi-square test was used in evaluating the qualitative data. In the assessment of quantitative data, the Mann-Whitney U or Student T-test was utilized in case of homogeneity between the two groups; whereas the One Way Anova test was used for comparison of more than two groups. For all data concerned,  $p < 0,05$  was considered statistically significant.

## Results

Pediatric patients were inserted CVC guided by fluoroscopy for 24 months. During this period, 87 central venous catheter interventions were realized by Anesthesiology and Reanimation Clinic on 56 pediatric patients. Fifteen (26,7%) of these patients had been catheterized recurrently. Catheters were applied to 41 patients in the neonatal intensive care unit, 32 patients in the pediatric department, 4 patients in the pediatric surgery department, and 2 patients in the neurosurgery department

(Figure 1).

All 87 catheter interventions were successful. Among them, 45 (51,7%) were applied on the right-hand side of the body, whereas 42 (48,3 %) were inserted on the left-hand side. Twelve (13,7%) of the catheter interventions were realised on patients under emergency conditions with a thrombocyte number less than 50.000/mm<sup>3</sup> (4 patients) and with high INR values (8 patients). In all these interventions, femoral location was preferred. For preventing hemorrhage in the catheter perimeter after the insertion, pressure was exerted after the application for control purposes. The average age of the catheterized patients was 5 months (1-28 months), and their average body weight was 4,64 (1-14) kg. Six (7%) of the interventions were applied from the femoral vein, 36 (41%) from the subclavian vein (34 from infraclavicular, 2 from supraclavicular area), 45 (52%) from the jugular vein.

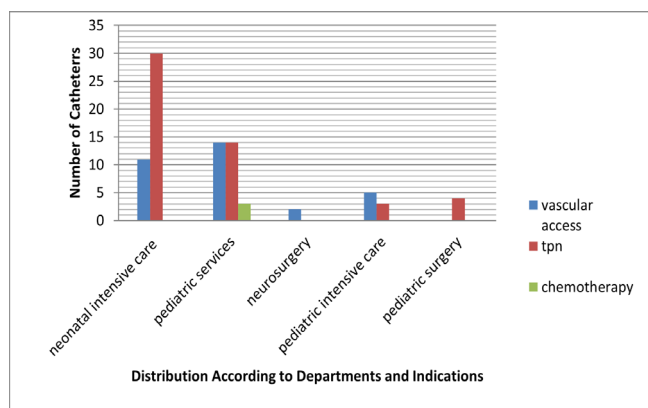
Of all the catheter interventions 32 (36,8%) were for establishing peripheric vascular access, 52 (59,8) were for total parenteral nutritional intravenous liquid and inotrope support, 3 (3,4%) were for chemotherapy purposes. In 41,4% (36) of the patients 4F, 16,1% (14) 5F, and in 42,5% (37), 5,5F two lumen catheters have been applied.

Complications emerging during the operation were evaluated in subtopics as malposition, pneumothorax, arterial puncture and others (arrhythmia etc.). In 29 of the 87 catheter interventions,

complications have emerged during insertion. The most frequent intervention complication was arterial puncture, which has been succeeded by pneumothorax in 3 (3,5%) patients. No malposition and catheter contortion have been observed during the operations. Patient's age, body weight, number of interventions and the location of catheterization were assessed as risk factors with respect to the development of intervention complications. With regard to age, no statistically significant difference was observed between the group with intervention complications and the group with no complications (p:0,25). A statistically significant difference was established in terms of body weight, number of interventions, and the location of catheterization (Table 1). When the catheter locations were evaluated for the occurrence of interventional complications, a statistically significant difference was detected. Complications were encountered more frequently in the right jugular and left subclavian areas (p=0,015). Among operational complications, arterial puncture, pneumothorax/hemothorax was encountered more frequently as the number of interventions increased (p:0,001). It has been established that operational complications increase as the body weight increases.

Complications, which have emerged during monitorisation were evaluated in subtopics as infection, thrombosis, and other (hemothorax, hydrothorax). With regard to the development of infections during catheter monitorisation, catheterisation period and the lumen diameter of the catheter were considered risk factors. Accidental removals and occlusion of the catheters were not evaluated in complications category. During monitorisation, out of 87 inserted catheters, complications were encountered on 21 (24,1%) of them. No statistically significant difference has been established with regard to the parameters of monitorisation risk factor between the group with infection and the group with no infection (Table 2).

Catheter-related blood stream infection was the most frequent complication during monitorisation. Infection was observed on 11(12,6%) out of 87 catheters. Leukocyte count, catheter diameter, catheter's period of stay, and insertion location have been evaluated as risk factors in the development of blood stream infection related to catheterization. No significant relations were established between infection development and these parameters (p>0,05). Since the study was conducted retrospectively, although blood cultures collected from the catheters were inspected for growth in patients with catheter-related blood stream infection, the microorganisms causing the infection and the existence of catheter entry point infection could not have been assessed. Thus, this constitutes the missing point of our research. Results of catheterization applications were as follows: in 17(19%) incidences, they were no longer needed, in 14 (16%) incidences, they were occluded, in 1 incidence, there was marginal leakage, in 1 another pneumothorax developed later, and in 21 (24,1) of the incidences catheters came off by spontaneous accidents. Twelve catheters were removed because the patients were deceased, and three catheterized patients were transferred to another health center. While there were no statistically significant differences between the catheter locations with regard to accidental withdrawals (p:0,47), they were proportionally encountered more frequently in subclavian areas.



**Figure 1.** Distribution of pediatric patients according to departments and indications

**Table 1.** Operational complications of the cases

	No Complications	Complications	p
Age(Month)	5,34±5,11	6,41 ±4,17	0,33
Weight(gram)	4,01±2,34	5,42±3,08	0,01*
Height (cm)	53,18±9,00	58,20±12,90	0,03*
BMI	23,7±7,4	28,8±13,3	0,001*
Numberof interventions	2,19±1,34	1,73±0,79	0,001*
Location of insertion			0,015*

**Table 2.** Monitorisation complications of the cases

	No Complications	Complications	p
Catheter diameter	4,78±0,69	4,86±0,74	0,5
Catheter stabilisation level	6,15±1,56	6,53±1,35	0,92
Cath period of stay (day)	19,09±11,31	15,53±8,68	0,02*
Leukocytcount	12502±7065	11673±4935	0,69

## Discussion

In our study, 36,7% of central venous catheterizations were applied, since peripheric vessel catheterization was not possible. Whereas in similar studies, the most frequent reason for this application is peripheric vessel catheterization. We consider that, since the applications were realized by anesthesiology and reanimation specialists, peripheric vessel catheterization operations have been successful, so that there has been no need for central venous catheterisation [4,5]. Furthermore, we suggest that a high success rate in catheterisation is due to experienced operators, and that interventions have been realized in OR conditions under sedoanalgesia with fluoroscopic guidance.

Patient's specifics and clinical experience of the operator should be taken into consideration while choosing catheter location. For every location to be chosen for catheterization there are distinctive advantages and disadvantages as well. While the subclavian and internal jugular locations carry less infection and thrombosis risk in extended uses, femoral location is safer with regard to mechanical complications. Moreover, it is more difficult to control hemorrhage in the subclavian area because of anatomical reasons [6-8]. In our hospital, most frequently utilized veins were subclavian vein 45 (51,7%), internal jugular vein 36 (41,4%), and femoral vein 6 (6,9%) consecutively. Although femoral location has been preferred by less experienced departments [9], based on the experience of specialists, subclavian vein has been utilised in our department because patient comfort is better and the existence of a shock does not affect the ratio of success, in spite of the fact that the intervention is technically harder and life-threatening complications are encountered more frequently. Ergül et al. preferred femoral location primarily in catheter interventions because life-threatening complications like pneumothorax have not been observed in this location, hemorrhages can be controlled more easily, access is easier, and the intervention does not obstruct cardiopulmonary resuscitation, although hematoma, arterial puncture, and thrombosis complications have been encountered frequently [3]. While jugular areas also have been preferred to a great extent because of less complication development, and easier control of hemorrhages, possible anatomical variations may cause failure. In our department, subclavian vein in children with less weight, jugular vein in children with higher weight, and femoral vein in children with hemorrhage disorder have been preferred.

The literature reports 1-42% of complications based on the intervention in catheter insertions [10,11]. In our study, the complication rate during CVC intervention was 33,3 (29/87). While it was stated that the most frequently encountered complication during the operation has been catheter malposition [12], in our study, 29,9% of them were arterial puncture and 3,4% were pneumothorax/hemothorax. We infer that, most frequent complications we have encountered have been arterial puncture, because the most frequently utilized intervention was subclavian. We attribute the absence of malposition and arrhythmia to the use of fluoroscopic guidance during the operation. Since fluoroscopy was utilized during the operation, there was no need for a routine chest X-ray after the intervention. Although some authors have stated that there has

been no need for a routine chest X-ray unless there is doubt about a complication, they have also remarked that frequent and thorough physical examination is necessary if the chest X-ray has not been taken [13,14].

CVC application is conducted with landmark technique in our department. Frequently encountered intervention complications have been mechanical ones, such as arterial puncture, pneumothorax, arrhythmia, malposition, and air embolism. Rarely reported complications are hemorrhage due to traumatization of main veins, airway injury, medulla spinalis trauma, chylothorax, pleural effusion, cardiac tamponade, catheter rupture, stay of the guide wire in the vein, development of fistule, hydrothorax, hemothorax, embolization of the ruptured catheter piece in the lungs, nerve damage, thrombosis in the vein where catheter is inserted, and hematoma in the intervention area [13]. Arterial puncture has been our most frequently encountered complication with 29,9%. This value is higher compared to the literature. Literature states the frequency of pneumothorax between 1,2% and 6% [5,9]. Our second most frequent complication has been pneumothorax with a rate of 3,4%, and it has been encountered only on subclavian catheters. Ergül et al. have established that serious complications have emerged in the subclavian area, and that femoral and jugular locations have been safer for pediatric patients [3]. In our study, among catheterization locations with regard to the existence of operational complications, they were encountered more frequently in the right jugular and left subclavian areas.

Ultrasonography-guided catheterization decreases all interventional complications, including pneumothorax [15,16]. Positioning of the catheter tip in the right atrium is the most frequent malposition. In CVC applications, catheter tip should be positioned right above the point of junction between right atrium and superior vena cava. Because of choosing wrong sized catheter for the patient, and forging more than needed, the catheter may reach the right atrium. The most effective method in detecting malposition is the utilization of bedside ultrasonography for viewing that the catheter is in the point of junction between vena cava superior and the right atrium [17]. Another method for preventing these kinds of complications is the placement of catheter with fluoroscopic guidance, as utilized in our study. Since the movements of the wire and the catheter can be monitored, improper placement of the catheter is out of the question [16].

Complications encountered during monitorisation were evaluated under subtopics as "infection", "thrombosis", and "other". The most frequent complications during monitorisation were catheter-related bloodstream infections. Although one might think that infections are more probable in the femoral area, because this area carries a higher risk of urine and feces contamination; recent studies have stated that there has been no significant difference between subclavian and jugular areas with regard to catheter infections. Likewise, no significant differences between these areas were established in our study as well. Catheter-related bloodstream infections in central venous catheters without tunnel change according to the catheter location, period of catheterization, and the lumen number of the catheter. Infection risk increases in catheters

with more than one lumen [18]. Ergül et al. have stated that the infection rate increases as the catheterization period is elongated. They indicate that utilization of central catheter cloths with chlorhexidine does not decrease the rate of infection; and that they are not suggested unless all other measures are taken but the catheter infection has not been eliminated [19].

Chung et al. have stated in their review that the risk of thrombosis may account for 0-50%; and they have accentuated that catheter type, catheter size, and the underlying disease play a role in the development of thrombosis. According to the literature, there is a higher probability of thrombosis in femoral vein compared to other locations. In femoral catheterizations lasting more than 5 days, utilizing ultrasonographic monitoring for thrombosis twice a week is an effective method for detecting thrombosis. Clinically asymptomatic thrombosis rates are higher than symptomatic ones [13,20]. No thrombosis was monitored among our patients.

Karapınar and Cura have evaluated the accidental extraction of the catheter as monitorization complication and reported its rate as 3,3% [9]. Among our cases, the rate of accidental extraction of the catheter was established with a significantly higher rate than in the literature as 15,5%. However, as in many studies, extraction and occlusion of the catheter were not defined as complications in our study as well.

### Conclusion

Central venous catheterization application is technically difficult in pediatric patients; various complications may be encountered during intervention and monitorisation. Increased experience of the physician and maintenance of proper conditions decrease the rate of catheter-related complications. Since more serious complications have been encountered in subclavian areas compared to femoral and jugular areas, primary choice should be femoral and jugular areas. We consider that utilization of fluoroscopy during operation decreases the rate of complications like malposition and arrhythmia.

### Scientific Responsibility Statement

The authors declare that they are responsible for the article's scientific content including study design, data collection, analysis and interpretation, writing, some of the main line, or all of the preparation and scientific review of the contents and approval of the final version of the article.

### Animal and human rights statement

All procedures performed in this study were in accordance with the ethical standards of the institutional and/or national research committee and with the 1964 Helsinki declaration and its later amendments or comparable ethical standards. No animal or human studies were carried out by the authors for this article.

**Funding:** None

### Conflict of interest

None of the authors received any type of financial support that could be considered potential conflict of interest regarding the manuscript or its submission.

### References

1. Kidney DD, Nguyen DT, Deutsch LS. Radiologic evaluation and management of malfunctioning long-term central vein catheters. *AJR Am J Roentgenol.* 1998;171(5):1251-7.
2. Fernandez EG, Sweeney MF, Green TP. Central venous catheters. In: Deckman RA, Fiser DH, Selbst SM (eds). *Pediatric Emergency and Critical Care Procedures.* St Louis: Mosby-Year Book, 1997:196-202.
3. Ergül AB, Özcan A, Aslaner H, Aslaner HA, Köse S, et al. Evaluation of central venous catheterization complications and related risk factors in a pediatric intensive care unit. *Journal of Critical and Intensive Care.* 2016; 7(1): 9.
4. İşgüder R, Gülfidan G, Ağın H, Devrim İ, Karaarslan U, Ünal N. Central venous catheterization applications in the pediatric intensive care unit: Four years of experience. *CAYD* 2014;1(1):31-8

5. Akyıldız B, Kondolot M, Akçakuş M, Poyrazoglu H, Tunç A, Hafizoğlu D, Ekici A. Evaluation of our patients who underwent central venous catheterization in the pediatric intensive care unit: our two-year experience. *Çocuk Sağlığı ve Hastalıkları Dergisi* 2009;52:63-7.
6. Parianti JJ, duCheyron D, Timsit JF, Traoré O, Kalfon P, Mimos O, Mermel LA. Meta-analysis of subclavian insertion and nontunneled central venous catheter-associated infection risk reduction in critically ill adults. *Crit Care Med.* 2012;40(5):1627-34.
7. Ge X, Cavallazzi R, Li C, Pan SM, Wang YW, Wang FL. Central venous access sites for the prevention of venous thrombosis, stenosis and infection. *Cochrane Database Syst Rev.* 2012;14(3):CD004084.
8. Bannon MP, Heller SF, Rivera M. Anatomic considerations for central venous cannulation *Risk Manag Healthc Policy.* 2011; 4:27-39.
9. Karapınar B, Cura A. Complications of central venous catheterization in critically ill children. *Pediatr Int.* 2007; 49(5):593-9.
10. Yılmazlar A, Bilgin H, Korfali G, et al. Complications of 1303 Central Venous Cannulations. *J R Soc Med.* 1997;90(6):319-21.
11. Gladwin MT, Slonim A, Landucci DL, Gutierrez DC, Cunnion RE. Cannulation of the internal jugular vein: is postprocedural chest radiography always necessary? *Crit Care Med.* 1999;27:1819-23.
12. Bailey SH, Shapiro SB, Mone MC, Saffle JR, Morris SE, Barton RG. Is immediate chest radiograph necessary after central venous catheter placement in a surgical intensive care unit? *Am J Surg.* 2000; 180(6):517-22.
13. Rey C, Alvarez F, De La Rua V, Medina A, Concha A, Díaz JJ, et al. Mechanical complications during central venous cannulations in pediatric patients. *Intensive Care Med.* 2009;35(8):1438-43
14. Ely EW, Hite RD, Baker AM, Johnson MM, Bowton DL, Haponik EF. Venous air embolism from central venous catheterization: a need for increased physician awareness. *Crit Care Med.* 1999;27(10):2113-7.
15. Dolu H, Goksu S, Sahin L, Ozen O, Eken L. Comparison of an ultrasound-guided technique versus a landmark-guided technique for internal jugular vein cannulation. *J Clin Monit Comput.* 2015;29(1):177-82.
16. Bowen ME, Mone MC, Nelson EW, Scaife CL. Image-guided placement of long-term central venous catheters reduces complications and cost. *Am J Surg.* 2014;208(6):937-41.
17. Reyes JA, Habash ML, Taylor RP. Femoral central venous catheters are not associated with higher rates of infection in the pediatric critical care population. *Am J Infect Control.* 2012;40(1):43-7.
18. Lee JH. Catheter-related bloodstream infections in neonatal intensive care units. *Korean J Pediatr.* 2011;54(9):363-7
19. Hewlett AL, Rupp ME. New developments in the prevention of intravascular catheter associated infections. *Infect Dis Clin North Am.* 2012;26(1):1-11.
20. Joynt GM, Kew J, Gomersall CD, et al. Deep Venous Thrombosis Caused by Femoral Venous Catheters in Critically Ill Adult Patients. *Chest.* 2000;117(1):178-83.

### How to cite this article:

Nevin Aydın, Osman Esen, Gülseren Yılmaz. Effect of fluoroscopy in central vein catheterization in children. *Ann Clin Anal Med* 2022;13(Suppl 1): S1-5